

Nutritional management of a senior horse with severe dental disease: a case report

Resident : Nicolas C Galinelli

Lab of Animal Nutrition Fac of Vet Med, Ghent University, Belgium.

Residency class

ESVCN Congress 2017

Cirencester, United Kingdom

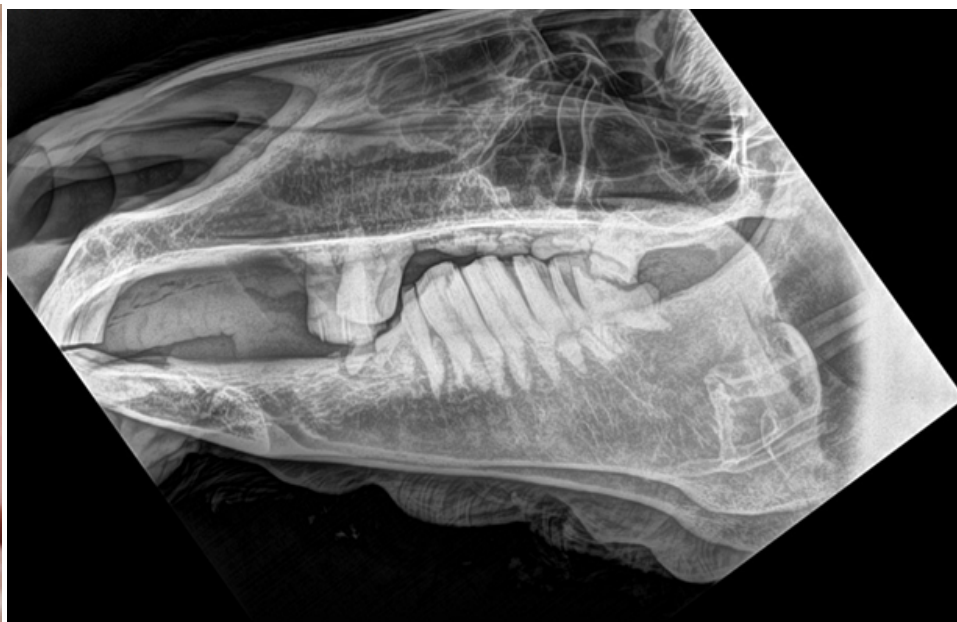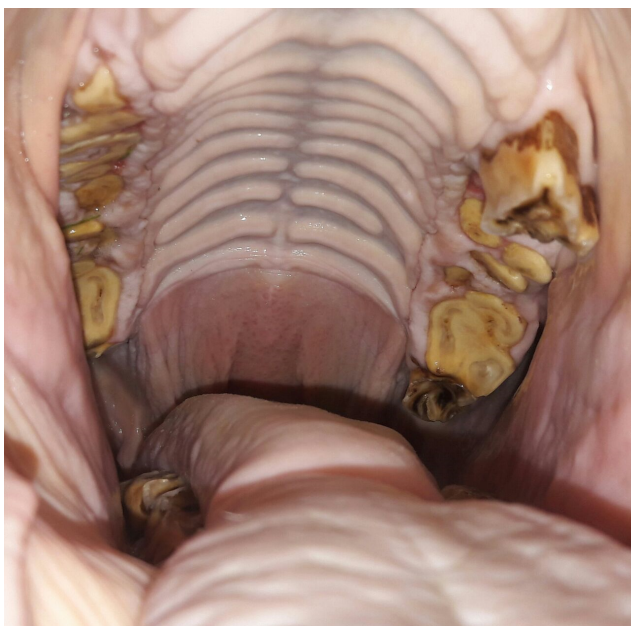
Introduction

Dental abnormalities present in 95.4 % of horses older than 15 years old

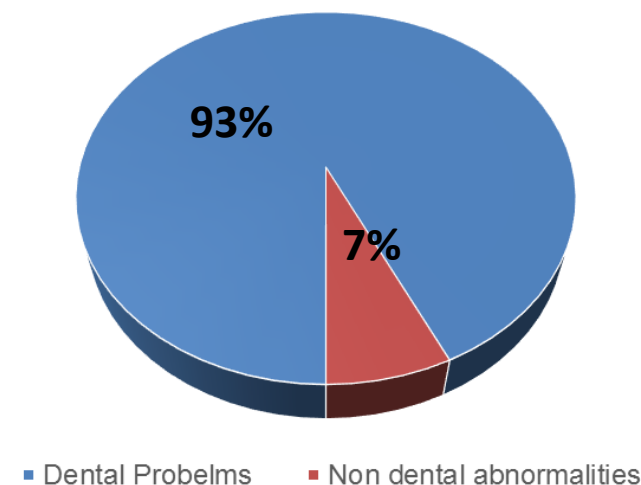
Other report, horses 30 years old: 32 % difficulties eating forage and 5.7 % eating both forage and concentrates

Common findings: diastemas, missing teeth, waves

Smooth mouth, it reduces the capacity to grind.



Donkeys more than 30 years old

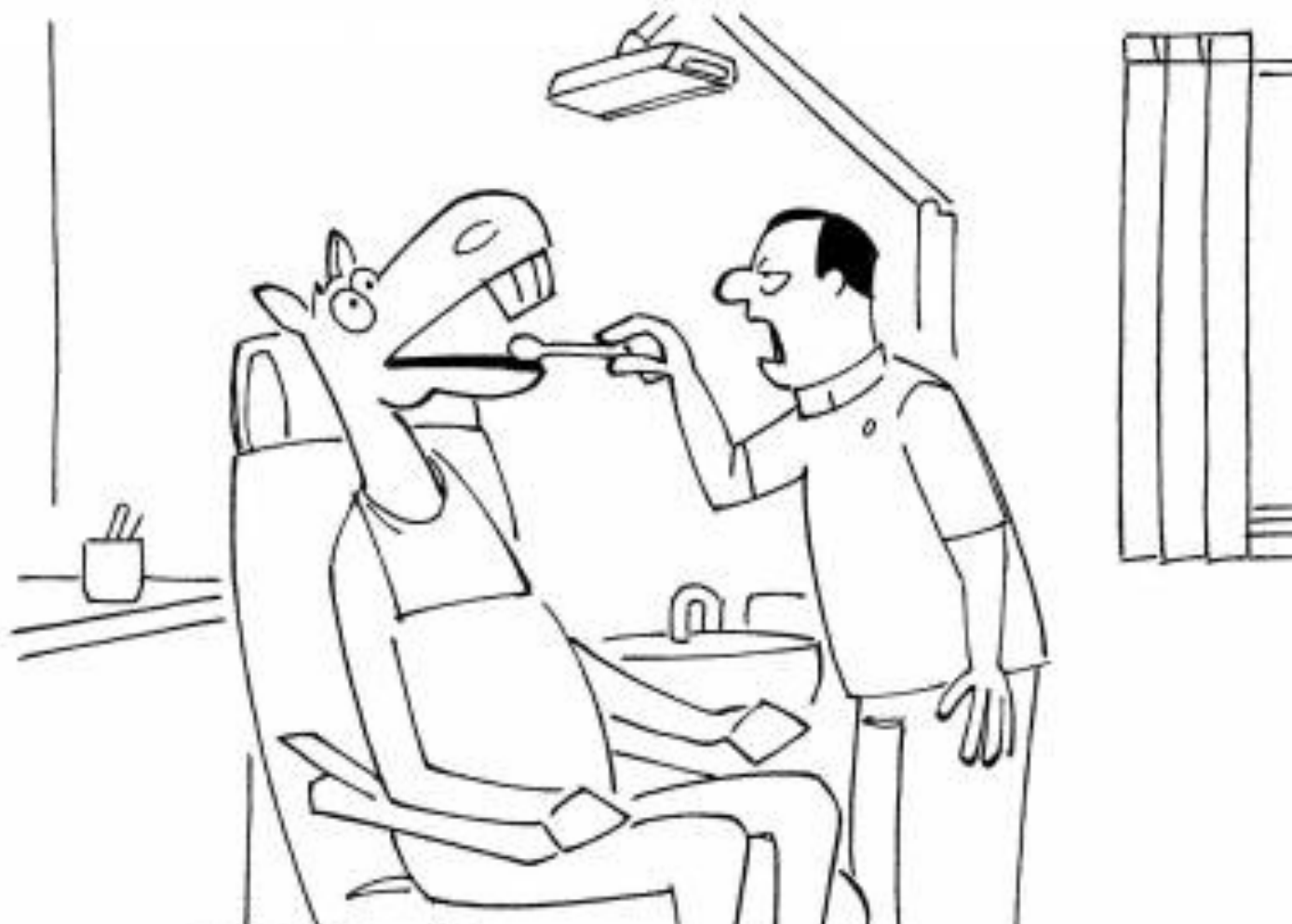

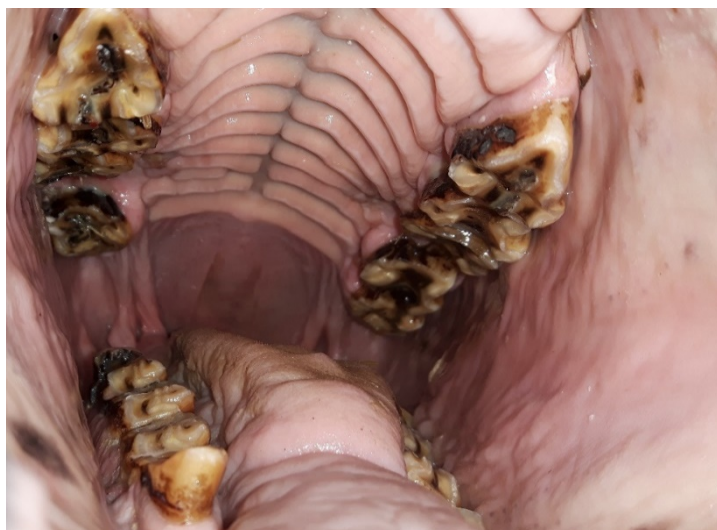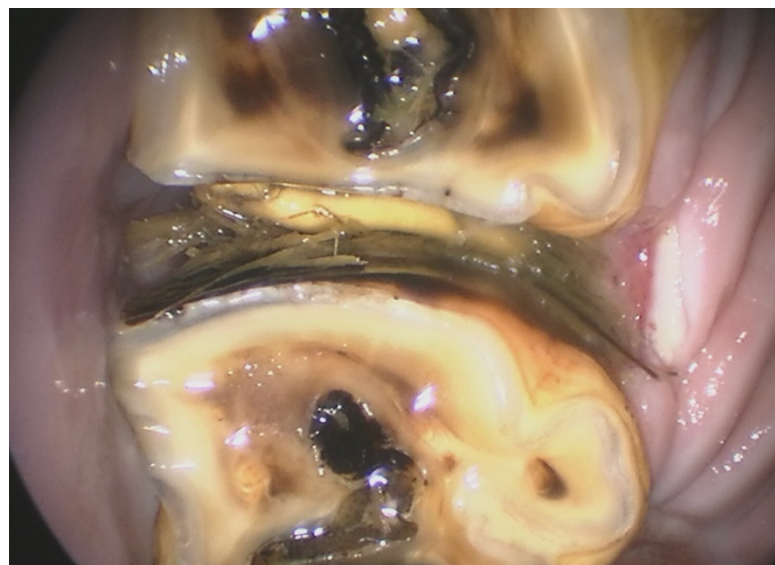
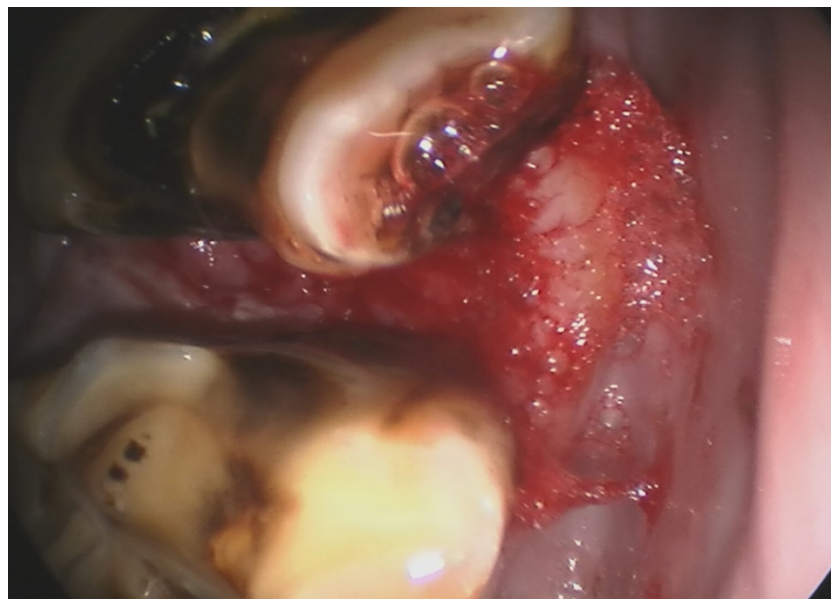Equine dental characteristics

- Hypsodont which means "high tooth"
- Hypsodont is a pattern of dentition with high-crowned teeth and enamel extending past the gum line, providing extra material for wear and tear.
- Teeth have a continuous eruption and the wear is compensated by new crown formation.
- After the age of 17, this compensation fades and the total length of the teeth shorten phenomenon called 'smooth mouth'.
- The enamel in the tooth disappears making the tooth softer ('smooth').
This condition reduces the capacity to grind the food.

CASE

- Breed: Pony
 - Sex: Female
 - Age: 21 years old
 - Current BW: 262kg
 - Activity: Recreation
- Retired from riding school





Veterinary surgeon: <u>Loo</u>		Date: <u>19/10/16</u>	
Patient file n°: <u>7084</u>		Horse: <u>Black Beauty</u>	Age: <u>21</u>
BW: <u>263</u> kg	BCS:	Sex: <u>✓</u>	Breed:
History: <u>Vertebral; molar popper; kneeling wrong leg</u>		Use:	

#1

#4

LMC before

#2

#3

#1

#2

Comments

electrode not secured

- not at 200 cables
- electrode left in place
- at 140 to 200 cables
- muscle pull sensor open
- electrode
- schappe contact pulses
- curve waveform
- HW 103-104

#4

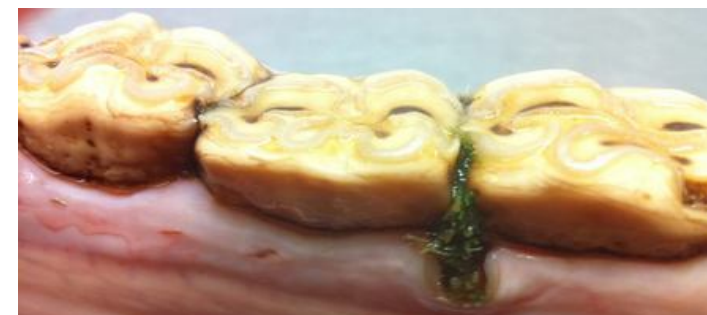#3

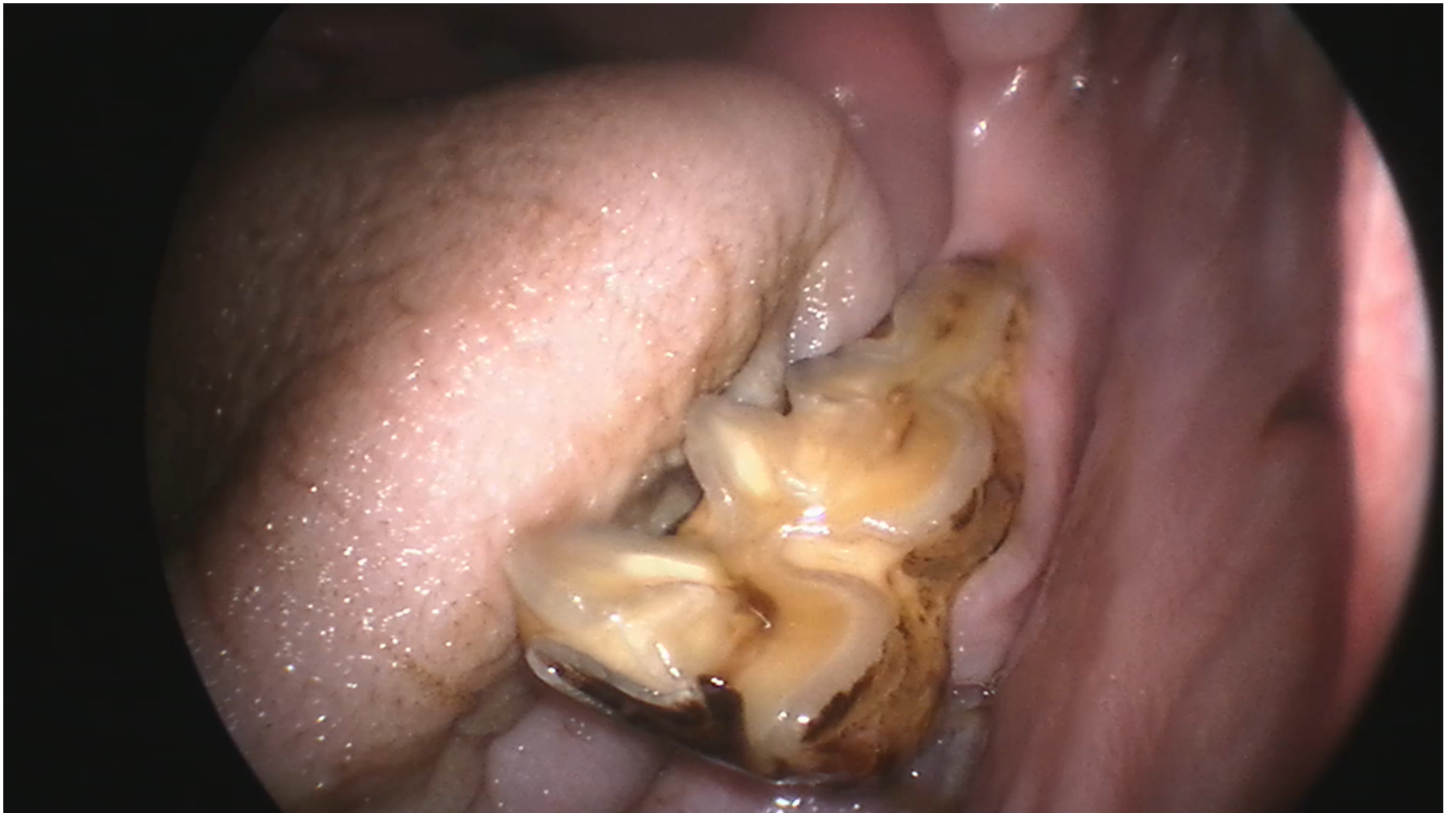Treatment: intermittent chondrolin

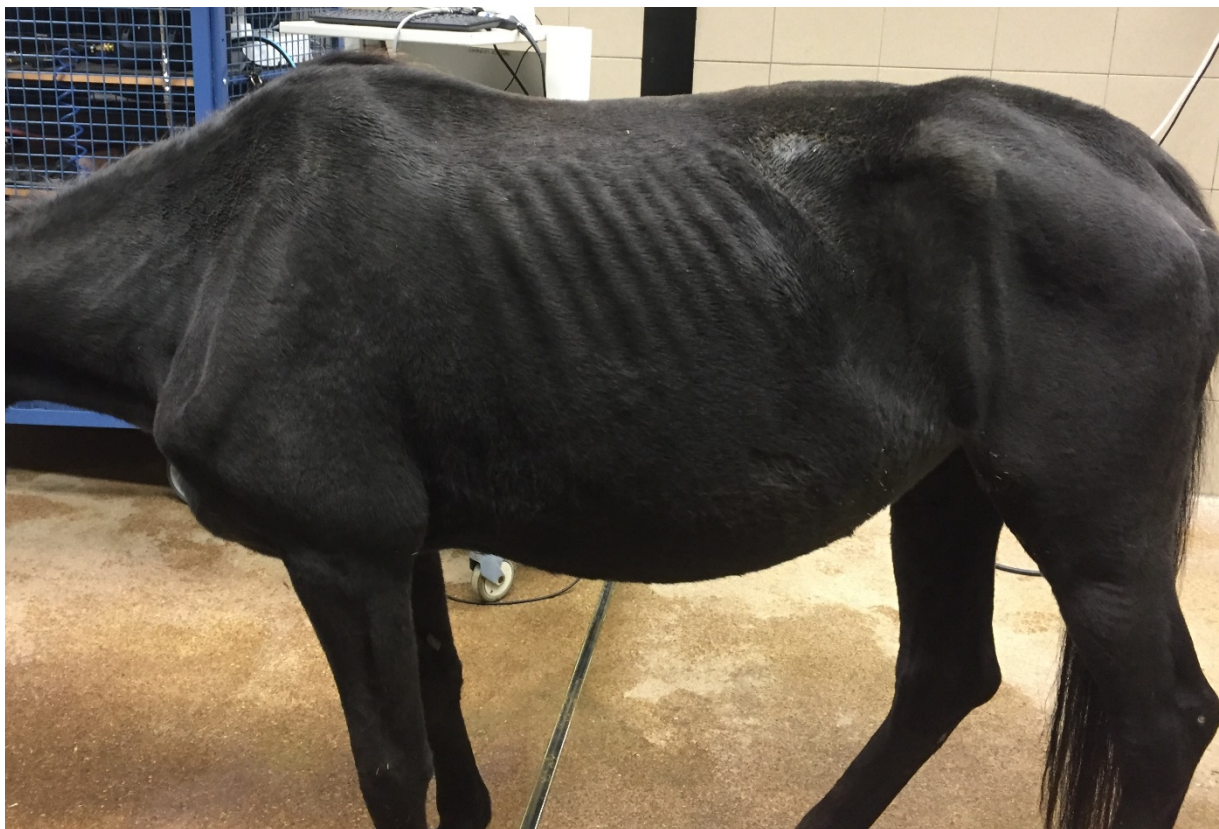• 1200mg 3x/day

• 1200mg 3x/day

• 1200mg 3x/day



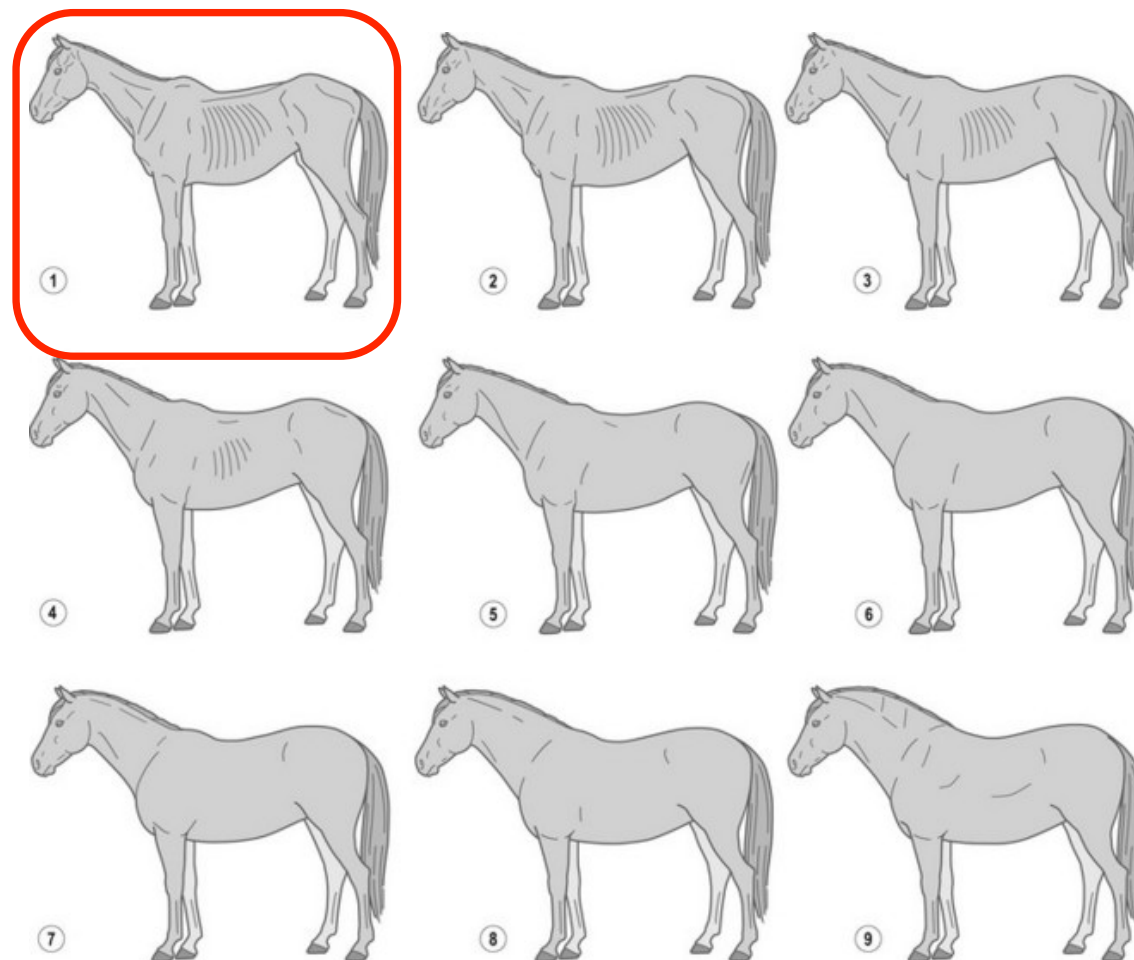




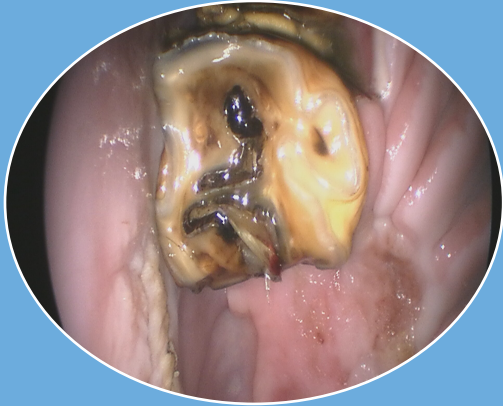
BCS 1/9

BW_{id} = 4/9 = 316kg

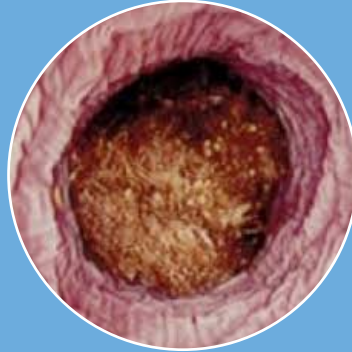
5/9 = 334 Kg.




Body Conditional Score



Teeth Problem
Fiber



Esofageal Obstruction
Prevent future
problems



BCS
Increase the BW

← Considerations for Nutritional Advise →

Evaluation of current diet

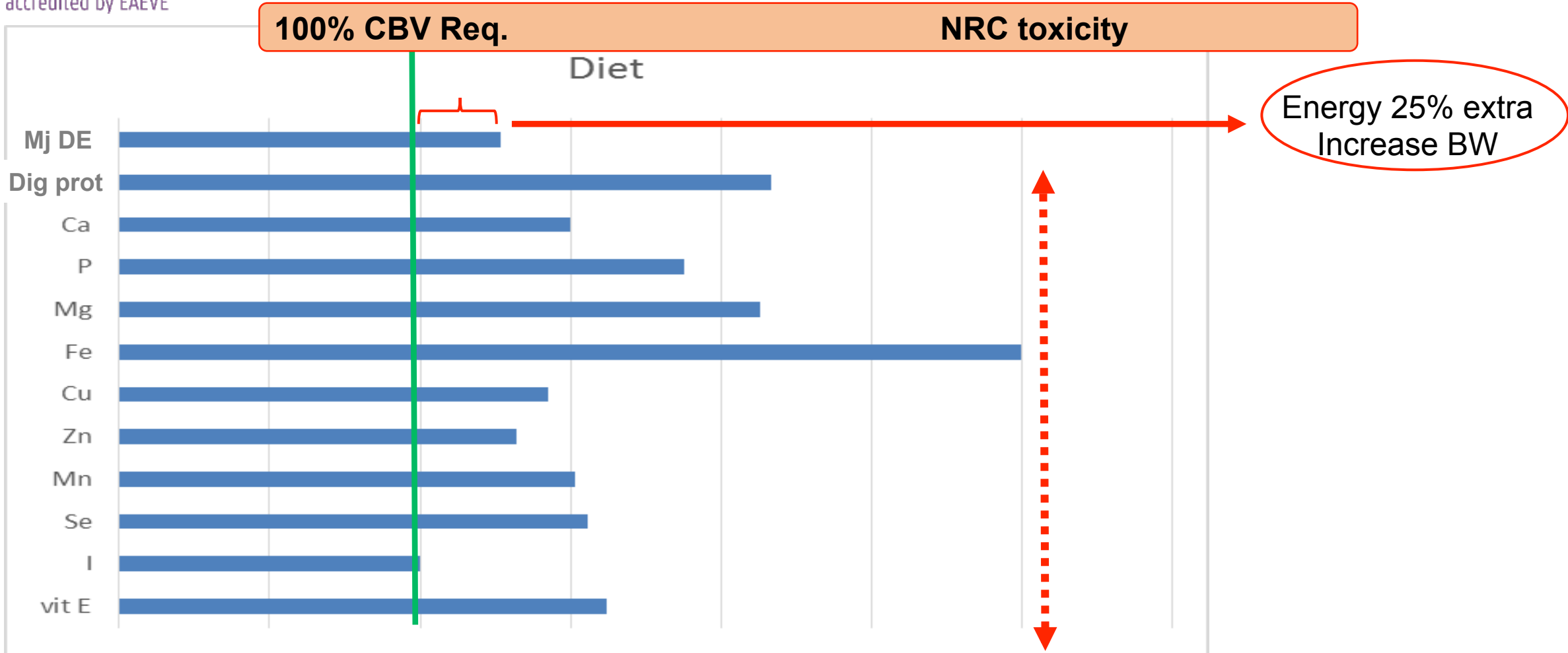
20 lts bucket



Dietary advice

- Beetpulp
- Grass Pellets
- Basic cubes
- Corn oil
- Mineral/Vitamin Supp.
- Yeast Supp.






C. Prot 10%DM C. Fat 3,0%DM C. Fiber 26,4%DM Sugar + Starch 8,5%DM

Comparison nutrients intake and requirements

Nutritional advise



- Dry matter Intake 1,5% IBW (5,1kg)
- Sugars and Starch: < 1,1g/BW/meal (0,39g/kg/meal)
- Feeding small but frequent meals aid in better digestion and absorption (Harris, 2007).
- Amount food volume (soaked food-soup) possible to eat:
9 - 11 l for a horse 450 kg BW
- Maximum volume 340 kg  6,2 l
- Diet volume: 1ml water/gr of food
Beetpulp 4ml water/1gr beetpulp
Total volume of diet = 7,2 l

Ideally in 4 meals ($7,2/4 = 1,8$ l)



Follow-up

- Acceptation of the diet
- Eating new complete formulated diet in 15 days
- Pony was very enthusiastic to eat new formulation
- Not other sign of esophageal obstruction was seen
- Pony increased 20 kg body weight in 1,5 month (282 kg, BCS 2-3/9)





References

- Du Toit N. (2011). Geriatric dentistry. In: Equine dentistry. 3th edn. Eds Easley J., Dixon P.M., Schumacher J. Saunders Elsevier. pp. 279-287.
- Geor R. J., Harris P. A. (2007). How to minimize gastrointestinal disease associated with carbohydrate nutrition in horses. In: Proc of the American Association of Equine Practitioners Orlando Florida, USA. AAEP, Lexington, KY. pp. 178-185.
- Henneke D. R., Potter G. D., Kreider J. L., Yeates B. F. (1983). Relationship between condition score, physical measurements and body fat percentage in mares. Equine Vet J. 15(4), pp. 371-372.
- Hoffman R. M. (2013). Chapter 8: Carbohydrates. In: Equine applied and clinical nutrition: health, welfare and performance. 1st edn. Eds Geor R. J., Coenen M., Harris P. Elsevier Health Sciences. pp.156-167.
- Ireland J. L., Clegg P. D., McGowan C. M., McKane S. A., Chandler K. J., Pinchbeck G. L. (2012). Disease prevalence in geriatric horses in the United Kingdom: veterinary clinical assessment of 200 cases. Equine Vet J. 44, pp. 101-106.
- Nicholls V. M., Townsend N. Geriatric (2016). Medicine. Dental Disease in Aged Horses and Its Management. Veterinary Clinics of North America: Equine Practice. 32(2), pp. 215-227.
- NRC, Nutrient requirements of horses (2007) The National Academies Press, Washington, 341pp.
- Raltson, S. L., Harris P. A. (2013). Chapter 15: Nutritional consideration for aged horses. In: Equine applied and clinical nutrition: health, welfare and performance. 1st edn. Eds Geor R. J., Coenen M., Harris P. Elsevier Health Sciences. pp. 289-303



Thank you very much your attention !!!!!!!

